



Not Your Father's Bladder Cells

Nicholas Mueller BS¹; Cory A. Christensen DO, MPH²; Rajeev K. Seth, MD^{2,3}

¹SUNY Upstate College of Medicine, ²SUNY Upstate Department of Ophthalmology & Visual Sciences, ³Retina-Vitreous Surgeons of Central New York

INTRODUCTION

- Bladder cancer is a carcinoma of the urothelium that lines the bladder lumen.
- 4% of new diagnoses present with metastatic disease.¹ Most common sites of metastases are lymph nodes, bones, lungs, liver, and peritoneum.²
- Most common intraocular site for metastatic cancers is choroid (90%); least common is retina (<1%).³ Intraocular metastasis from bladder cancer are infrequent. Retinal metastasis from bladder cancer are even rarer with only 1 known documented case.⁴
- We describe the second known case of bladder cancer metastasizing to the retina.

CASE

- 86M w/ Dry AMD OU, macular hole S/P repair OS, PCIOL OU, referred for iritis and blurry vision OS s/p YAG capsulotomy
- PMH of bladder cancer, lung cancer, COPD
- Initiation of topical prednisolone resolved iritis OS
- BCVA following iritis was 20/50 OD, 20/70 OS
- Followed-up 5 months later for persistent blurry vision OS
- DFE OS revealed focal area of yellow/green discoloration superotemporally w/ adjacent subretinal hemorrhage, suspicious for retinitis vs granuloma vs non-specific lesion
- Subsequent follow-ups, developed panuveitis, recurrent vitreous hemorrhage, and serous retinal detachment OS
- Failed PO Treatments:** Valtrex, Bactrim, and Prednisolone
- Procedures:** vitreous tap, STK injection, PPV w/ vitreous biopsy, and eventual repeat PPV for retinal biopsy
- Labs:** elevated IL-6, low-positive ANA (positive DS-DNA), and mildly elevated lysozyme
- Vitreous Cytology:** histiocytes and atypical epithelioid cells; no definitive neoplastic cells seen
- Retinal Biopsy Pathology:** metastatic cells consistent w/ urothelial carcinoma

DIAGNOSTIC TESTING

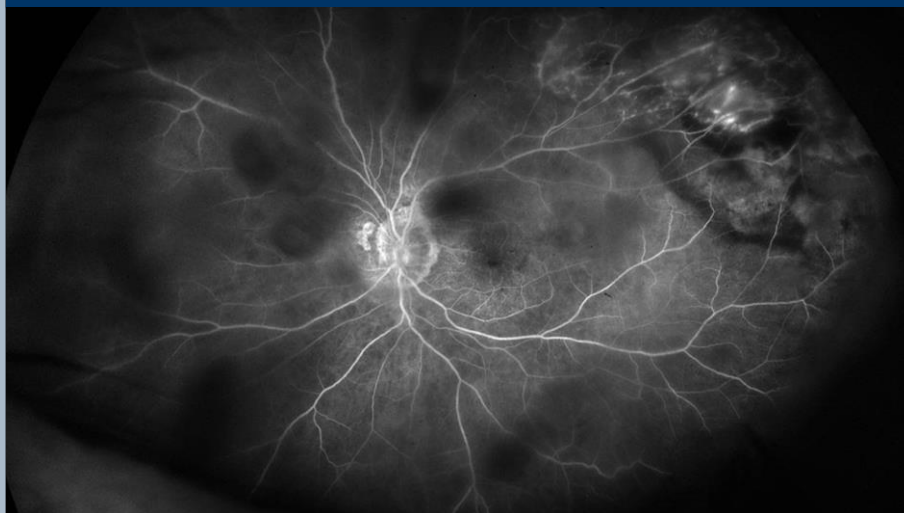

Figure 1: Late Phase IVFA OS w/ superotemporal media opacity consistent w/ vitreous debris, large heterogeneous lesion w/ coalescent areas of blockage, surrounding hyperfluorescent punctate staining consistent w/ microaneurysms, and diffuse capillary nonperfusion with late leakage.

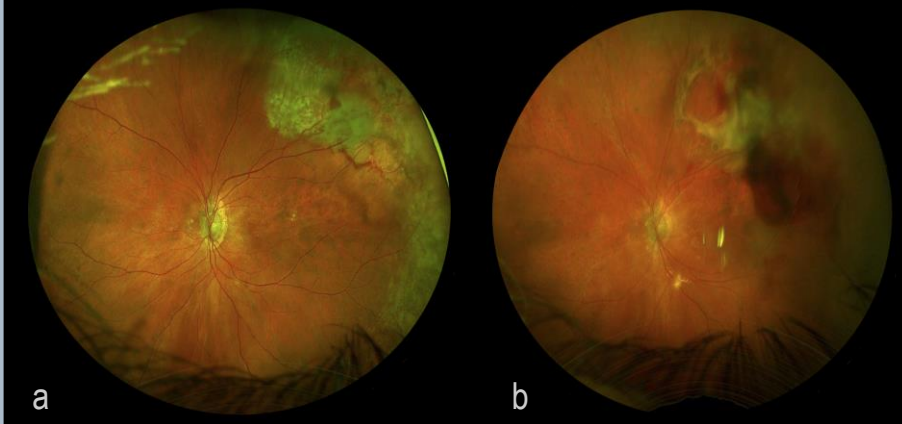


Figure 2a: Color Fundus Photography OS at time of presentation revealing large superotemporal yellow/green lesion and associated subretinal hemorrhage.

Figure 2b: Color Fundus Photography OS S/P PPV w/ retinal biopsy revealing biopsied retina w/ resolving subretinal hemorrhage and new inferotemporal yellow/green lesion

DISCUSSION

- Metastatic bladder cancer to the retina is rare.
- Confirmation is w/ retinal biopsy unless definitive CT/MRI findings are present.
- Initial ddx included infectious/inflammatory retinitis, granulomatous uveitis (sarcoidosis), or lymphoma, however Oncology and Rheumatology workups were unrevealing.
- Serous retinal detachment was the inciting factor for PPV w/ retinal biopsy.
- The previously documented case of metastatic bladder cancer to the retina presented similarly, w/ a non-specific white retinal lesion w/ surrounding subretinal fluid and abnormal vascular communication between the lesion and surrounding retina.⁴
- Standard treatment involves external/plaque radiotherapy and/or systemic chemotherapy dependent upon the spread of disease.³
- Retinal metastasis of any origin are associated w/ poor prognosis. In a case series of 8 patients with various retinal metastases, 5 died within 1 month of diagnosis.⁵
- Our case subsequently developed new lung nodules and is currently undergoing radiotherapy w/ favorable response. Commencement of chemotherapy will begin shortly.
- Most recent DFE revealed complete regression of initial superotemporal lesion and early regression of new inferotemporal lesion.

REFERENCES

- Lenis AT, Lee PM, Chama K, Mohs MD. Bladder Cancer: A Review. *JAMA*. 2020;324(19):1980-1991.
- Shangare AB, Ramayya NH, Jagannathan JP, Ferrassy FM, Taplin ME, Van den Abbeele AD. Metastatic pattern of bladder cancer: correlation with the characteristics of the primary tumor. *AJR Am J Roentgenol*. 2011;186(1):117-122.
- Shields CL, Kabralidis N, E. Gal M, et al. Metastatic tumours to the eye: Review of metastasis to the iris, ciliary body, choroid, retina, optic disc, vitreous, and/or lens capsule. *Eye*. 2017;31:809-814.
- Whalen KE, Eagle RC Jr, Vitabec TR. Case of metastatic urothelial carcinoma of the retina and vitreous. *Retin Cases Brief Rep*. 2018 Summer;12(3):177-180.
- Shields CL, McMahon JF, Atabay HT, Hasanmesoglu M, Shields JA. Retinal Metastasis From Systemic Cancer in 8 Cases. *JAMA Ophthalmol*. 2014;132(11):1303-1308.



This study was funded in part by unrestricted grants from Research to Prevent Blindness, Inc. New York, New York and Lions District 20-V1, Syracuse, New York. No other significant financial interests or relationships to disclosure

