



# Assessing Legal Blindness using Visual Field Testing in Uveitis

Bijal Kikani, BS<sup>1</sup>; Gwendolyn Schultz, MD<sup>2</sup>; Robert Swan, MD<sup>2</sup>

SUNY Upstate Medical University, Norton College of Medicine, Syracuse, NY<sup>1</sup>

SUNY Upstate Medical University, Department of Ophthalmology & Visual Sciences, Syracuse, NY<sup>2</sup>

## INTRODUCTION

- Legal blindness is defined by either a central visual acuity of 20/200 or worse in the better-seeing eye with best correction or a visual field of 20 degrees or less in the better-seeing eye.<sup>1</sup>
- Defining legal blindness is important for acknowledging patients who cope with visual challenges on a daily basis and defines eligibility for social support and financial benefits. These include, but are not limited to, eligibility for vocational training, rehabilitation, schooling, IRS tax exemption, and services such as audible books.
- Uveitis can cause devastating visual loss and can account for up to 20% of legal blindness,<sup>2-5</sup> but legal blindness may go undetected if both visual acuity and visual field are not measured.
- Here, we describe two cases of uveitis that meet the label of legal blindness based on visual field restriction.

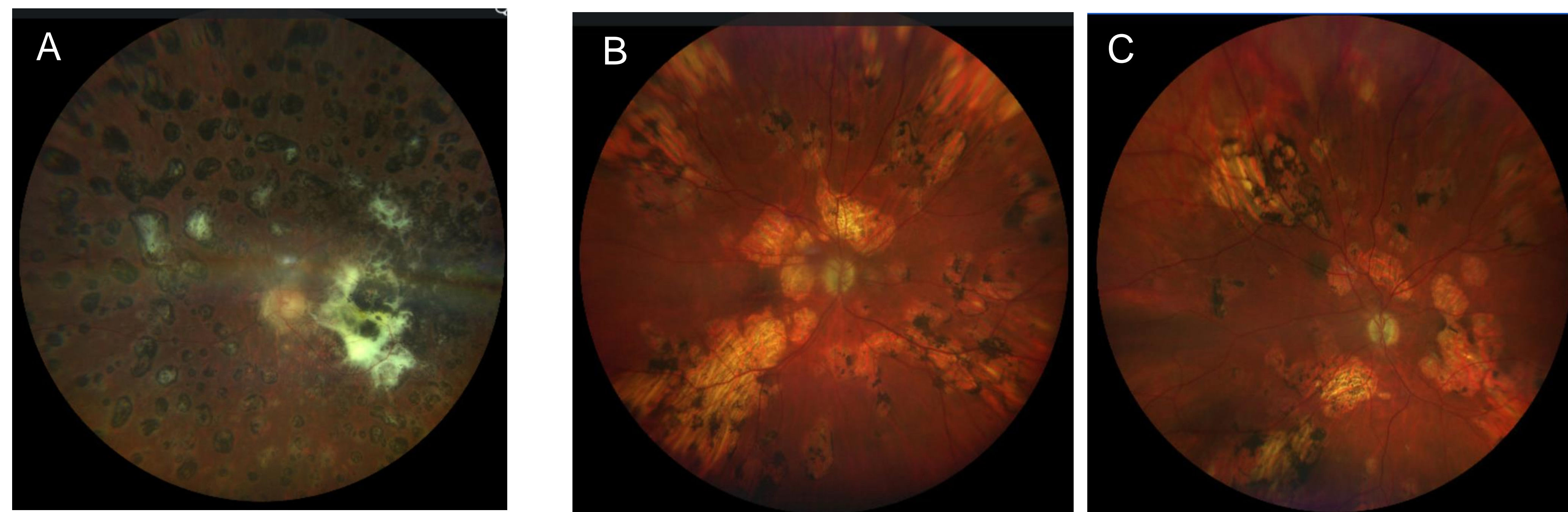
## CASE SERIES PRESENTATION

- The first case is a 19-year-old male who has no light perception (NLP) in the right eye from a shrapnel injury and was diagnosed with sympathetic ophthalmia in the left eye.
- The patient was functionally monocular with best corrected visual acuity of 20/150 in the left eye (**Figure 1**).
- Fundoscopic exam revealed extensive subretinal fibrosis in the macula and diffuse fibrosis in the periphery in the left eye (**Figure 2A**).
- Visual field testing of the left eye showed severe constriction (**Figure 3A**).
- The second case is a 50-year-old male with chorioretinitis of unknown etiology.
- At his last visit, his best corrected visual acuity was 20/80 in the right eye and 20/1600 in the left eye (**Figure 1**).
- Fundoscopic exam revealed optic nerve pallor, diffuse chorioretinal scarring, and patchy atrophy in both eyes (**Figure 2B, 2C**).
- Visual field testing demonstrated severe constriction in both eyes (**Figure 3B, 3C**).

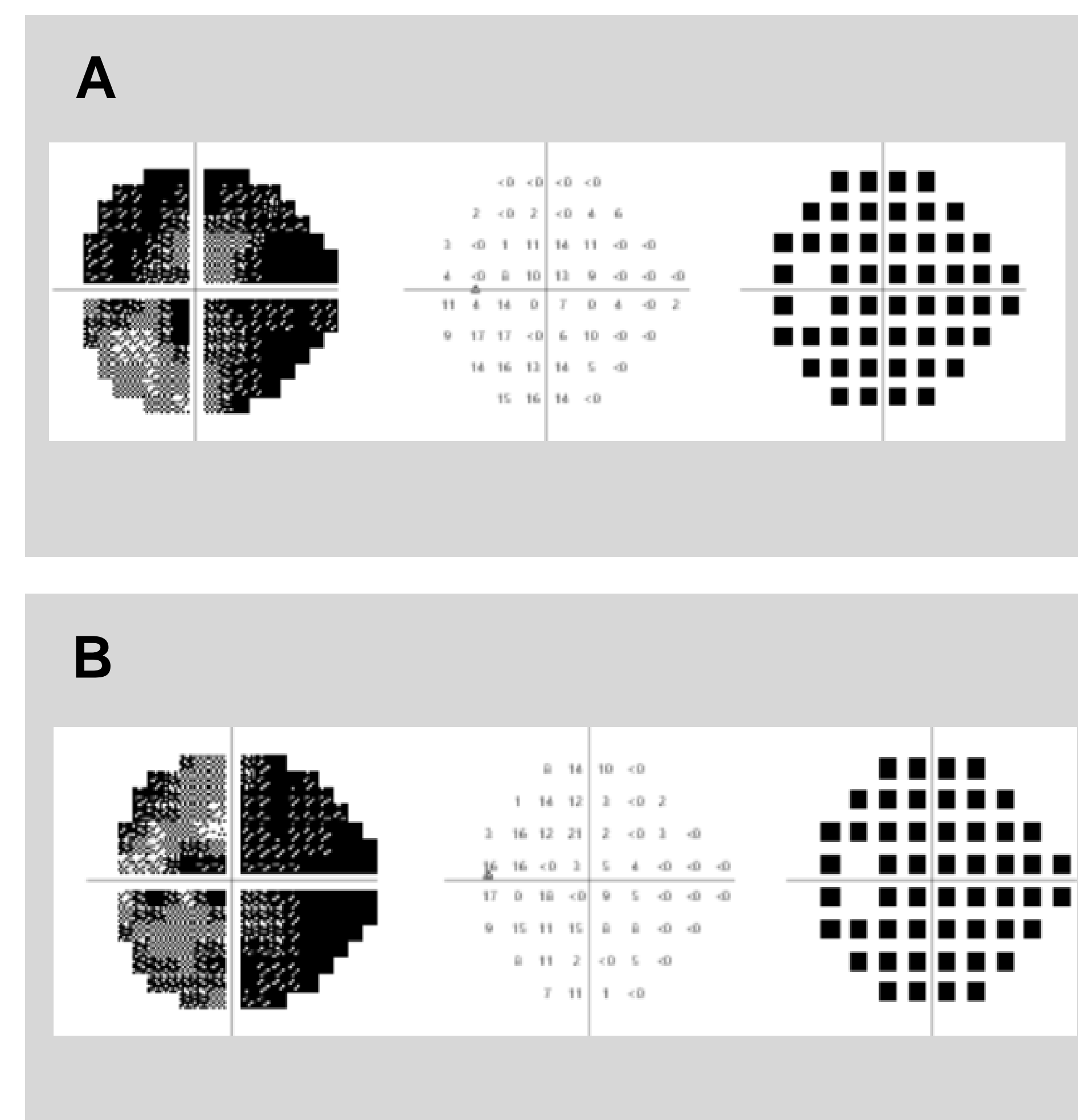
## OPHTHALMIC TESTING

Patient	BCVA, OD	BCVA, OS
1	NLP	20/150
2	20/80	20/1600

**Figure 1.** Best Corrected Visual Acuity (BCVA) of both eyes in patient 1 (19-year-old male) and patient 2 (50-year-old male).



**Figure 2.** Fundus photographs. **(A)** Left eye of 19-year-old male with sympathetic ophthalmia. **(B)** Right eye and **(C)** left eye in a 50-year-old male with chorioretinitis.



**Figure 3.** Humphrey Visual Field 24-2. **(A)** Left eye in a 19-year-old male. **(B)** Left eye and **(C)** right eye in a 50-year-old male. Total Deviation plots only - Mean Deviation threshold exceeded in all fields.

## DISCUSSION

- Uveitis is a group of intraocular inflammatory disorders with varying prevalence around the world.<sup>6</sup>
- In developed countries, it is the 5<sup>th</sup> most common cause of total blindness and accounts for up to 20% of legal blindness,<sup>2-5</sup> with one study reporting that 22% of patients with uveitis had legal blindness at some point in their follow-up.<sup>6</sup>
- While many uveitis patients undergo extensive testing including visual acuity, pupillary reactions, slit lamp examination, intraocular pressure measurement, fundoscopy, and ophthalmic imaging,<sup>6</sup> it is equally important to assess their visual fields to fully capture all cases of legal blindness.
- Both of our patients satisfied the requirements for legal blindness based on their visual field testing, but not visual acuity.

## CONCLUSION

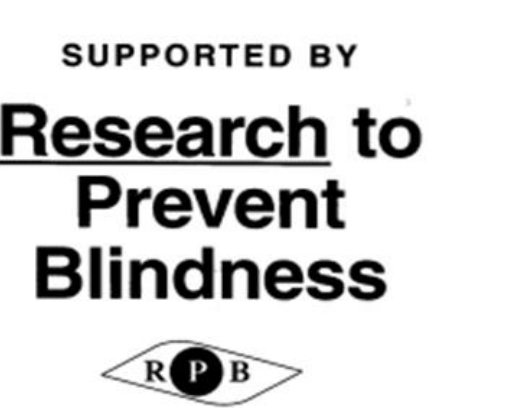- We report two patients with uveitis who have significant peripheral scarring and visual field loss.
- In patients with diffuse peripheral retinal scarring and uveitis, consider visual field testing for proper and timely diagnosis of legal blindness.
- Accurate and timely diagnosis of legal blindness can provide patients with access to services that can improve their quality of life.

## REFERENCES

1. Lee SY, Mesfin FB. Blindness. 2023 Jan 21. In: StatPearls [Internet]. Treasure Island (FL): StatPearls Publishing; 2024 Jan-. PMID: 28846303.
2. Darrell RW, Wagner HP, Kurland LT. Epidemiology of uveitis: incidence and prevalence in a small urban community. *Arch Ophthalmol* 1962;68:502-14.
3. ten Doesschate J. Causes of blindness in the Netherlands. *Doc Ophthalmol* 1982;52:270-85.
4. Krumpaszky HG, Klaus V. Causes of blindness in Bavaria. Evaluation of a representative sample from blindness compensation records of Upper Bavaria. *Klin Monatsbl Augenheilkd* 1992;200.
5. Nussenblatt RB. The natural history of uveitis. *Int Ophthalmol* 1990;14:303-8.
6. Durrani OM, Tehrani NN, Marr JE, Moradi P, Stavrou P, Murray PI. Degree, duration, and causes of visual loss in uveitis. *Br J Ophthalmol*. 2004 Sep;88(9):1159-62. doi: 10.1136/bjo.2003.037226. PMID: 15317708; PMCID: PMC1772296.



This study was funded in part by unrestricted grants from Research to Prevent Blindness, Inc. New York, New York and Lions District 20-Y1, Syracuse, New York. No other significant financial interests or relationships to disclosure



SUPPORTED BY

Research to Prevent Blindness

